

CASE REPORT

DORZOLAMIDE THERAPY IN X-LINKED RETINOSCHISIS AS EVALUATED BY SPECTRAL-DOMAIN OPTICAL COHERENCE TOMOGRAPHY.

Nagesha C.K¹, Narendra P. Datti², Sugaranjini G³

HOW TO CITE THIS ARTICLE:

Nagesha C.K, Narendra P. Datti, Sugaranjini G. "Dorzolamide Therapy in X-linked Retinoschisis as evaluated by Spectral-Domain Optical Coherence Tomography". Journal of Evolution of Medical and Dental Sciences 2014; Vol. 3, Issue 03, January 20; Page: 714-717, DOI:10.14260/jemds/2014/1891

ABSTRACT: A 23 year old adolescent presented with diminished vision in both eyes since childhood. Examination revealed best corrected visual acuity of 20/200 with absent foveal reflex on indirect ophthalmoscopy. Further imaging with SD-OCT revealed schisis cavities in fovea and parafoveal region. A course of topical dorzolamide was tried for a period of 8weeks, which showed improvement in terms of decrement in macular volume morphologically but this did not turn into functional visual gain. This case highlights role of SD-OCT in detecting subtle maculae pathologies and also in evaluating effectiveness of dorzolamide therapy in improving visual potentials.

KEYWORDS: Dorzolamide, Fundus fluorescein angiography, Retinoschisis, Spectral-domain Optical coherence tomography.

INTRODUCTION: X-linked retinoschisis (XLRS) is a rare hereditary retinal disease with a prevalence of about 1:120000 to 1:20 000.¹ It is associated with a mutation in the XLRS₁ gene located on the short arm of X chromosome, X_p22.² Although considered a rare condition it is among the commonest cause of juvenile macular degeneration.³ Recently, Spectral domain Optical coherence tomography (SD-OCT) has revolutionized the understanding of macular diseases; in schisis it helps to study morphological features of cavities and its behavior over a period of time.⁴ Though there is no cure for XLRS, various treatment approaches have been described in literature and still being tried to flatten the schisis cavities thereby possibly improving the visual potentials. Here, we described XLRS with special reference to SD-OCT before and after treatment with Dorzolamide therapy.

CASE HISTORY: A 23yr old adolescent presented for evaluation of decreased vision in both eyes in outpatient department. He complained of poor vision since childhood but worsened since last 2years. The Best corrected visual acuity (BCVA) was 20/200 in both eyes not improving with manifest refraction. Further evaluation with indirect ophthalmoscopy revealed absent foveal reflex with spoke like pattern in fovea. (Fig1&2) SD-OCT (Cirrus™; Carl Zeiss Meditech Dublin, CA) analysis with macular cube 512 ×218 revealed schisis within fovea of both eyes. A large central cyst extending from nerve fiber layer NFL to outer retina with severe thinning of NFL was seen and the same had protruded into the vitreous.(Fig3&4) The schisis was predominantly located between outer nuclear and inner plexiform layer but NFL schisis which is classical of juvenile retinoschisis was seen only at the parafoveal region.

Fundus fluorescein angiography (FFA) revealed no leakage even in late phase. A diagnosis of juvenile macular retinoschisis was made and treatment was started with topical Dorzox 2% (Dorzolamide hydrochloride 2% w/v; Cipla Pharmaceuticals Ltd.) 12hrly and was followed-up for 8 weeks. At the end of 8 weeks therapy, the average macular thickness and macular cube volume decreased slightly but central cyst height increased on OCT analysis. (Table: 1)(Fig 5&6). But in the

CASE REPORT

due course, this reduction in thickness could not be converted into gain in visual acuity. The VA at the end of 4 months follow-up was 20/200 in both eyes. After futile exercise with drug regimen, patient was referred to low vision service and genetic counseling.

Parameter	OD		OS	
	Before therapy	After therapy	Before therapy	After therapy
Central subfield thickness (μm)	494	539	508	541
Macular cube volume (mm^3)	11.5	11.1	11.9	11.7
Macular cube average thickness (μm)	320	310	330	314

Table 1: showing various macular quantitative parameters before and after treatment.

DISCUSSION: XLRs has been reported worldwide in whites,⁵ black⁶ and Asian people.⁷ Foveal schisis is characteristic of XLRs occurring in 90-100% of patients.⁸ Although considered a rare condition it is much underdiagnosed and recent imaging modalities have explained structural features of XLRs well thereby making diagnosis easier.

The presence of any pathology in early or subtle cases may not be evident from the clinical fundus examination. Given the enhanced detail available with OCT the early retinal changes may be visualized and diagnosis made earlier in patients suspected to have the disease. In this regard, Spectral Domain-OCT (SD-OCT) has improved image clarity and reduced motion artifact compared to previous Time-domain OCT.^{9,10}

Management of retinoschisis was basically referral to Low vision aids and genetic counseling. Recently, case reports and series have been published reporting the effectiveness of topical Brinzolamide¹¹ and Dorzolamide¹² in decreasing the cystic cavities of schisis. Attempt to flatten peripheral retinoschisis by treating the outer leaf with laser photocoagulation¹³ and managing the complications by vitrectomy¹⁴ have been associated with high incidence of post-operative complications.

Mohamed et al¹² studied effectiveness of sustained topical dorzolamide 2% for macular schisis. Among 29 eyes, 69% showed flattening of schisis and 55% had improved BCVA by at least 7 letters. In present case the macular cube average thickness decreased from 320 μm to 310 μm in OD and 330 μm to 314 μm in OS but it did not result in gain in visual acuity. The central schisis cavity increased in dimension without any clinical significance.

To conclude, effectiveness of topical carbonic anhydrase inhibitors decreased the severity of macular cysts on SD-OCT. Its clinical significance in terms of visual acuity gain still remains inconclusive. Further studies need to confirm these findings.

REFERENCES:

1. Rudanko SL, Flage T, Hansen E et al. Visual impairment in Nordic children. V. X-linked juvenile retinoschisis. *Acta Ophthalmol (Copenh)* 1993; 71:586-589.
2. Magnus JA. Case of retinal detachment in a child (? Cystic,?congenital). *Trans ophthalmol soc UK* 1951;71:728-30.
3. Manschot WA. Pathology of hereditary juvenile retinoschisis. *Arch ophthalmol.* 1972;88:131-8.

CASE REPORT

4. Theodore Leng. Two cases of X-linked retinoschisis with different spectral domain optical coherence tomography findings. *Clin Ophthalmol.* 2012-6:1563-1565.
5. AF. Sex-linked juvenile retinoschisis. In: Deutman AF, ed. *The hereditary dystrophies of the posterior pole of the eye.* Assen, the Netherlands: Van Gorcum, 1971: 48-98.
6. Ide CH, Wilson RJ. Juvenile retinoschisis. *Br Jf Ophthalmol* 1973; 57:560-2.
7. Miyake Y, Miyake S, Yanagida K. X-chromosomal congenital retinoschisis. *Acta Soc Ophthalmol Jpn* 1981; 83: 97-112.
8. Deutman AF. Sex-linked juvenile retinoschisis. In: Deutman AF, ed. *The hereditary dystrophies of the posterior pole of the eye.* Assen, the Netherlands: Van Gorcum, 1971: 48-98.
9. Wojtkowski M, Bajraszewski T, Targowski P, Kowalczyk A. Real-time in vivo imaging by high-speed spectral optical coherence tomography. *Opt Lett.* 2003;28:1745–1747. [PubMed]
10. Yun SH, Boudoux C, Tearney GJ, Bouma BE. High-speed wavelength-swept semiconductor laser with a polygon-scanner-based wavelength filter. *Opt Lett.* 2003;28:1981–1983.
11. Yang FP, Willyasti K, Leo SW. Topical brinzolamide for foveal schisis in juvenile retinoschisis. *J AAPOS.* 2013 Apr;17(2):225-7
12. Mohamed A. Genead, MD; Gerald A. Fishman, MD; Saloni Walia, MD. Efficacy of Sustained Topical Dorzolamide Therapy for Cystic Macular Lesions in Patients With X-Linked Retinoschisis. *Arch Ophthalmol.* 2010;128(2):190-197.
13. Brockhurst R. Photocoagulation in congenital retinoschisis. *Arch Ophthalmol* 1970; 84: 158-65.
14. Yu H, Li T, Luo Y, Yu S, Li S, Lei L et al. Long-term outcomes of vitrectomy for progressive X-linked retinoschisis. *m J Ophthalmol.* 2012 Aug;154(2):394-402.

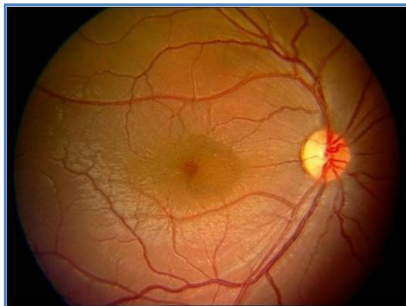


Fig. 1: Colour fundus photo of Right eye

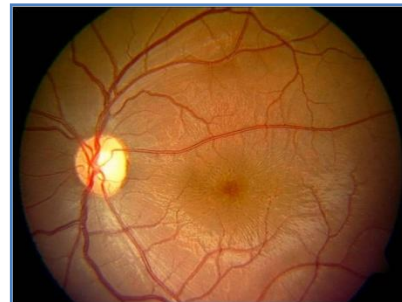


Fig. 2: Colour fundus photo of left eye

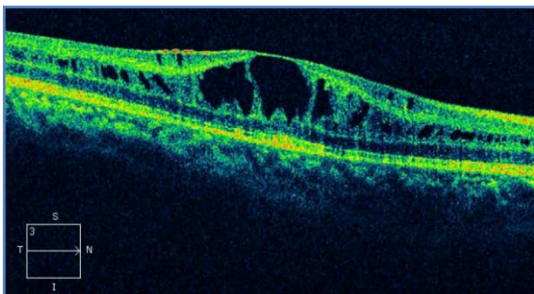


Fig. 3: sdopt 5line raster of right eye before treatment

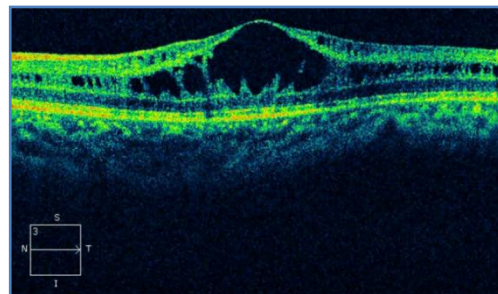


Fig. 4: sdopt 5line raster of left eye before treatment

CASE REPORT

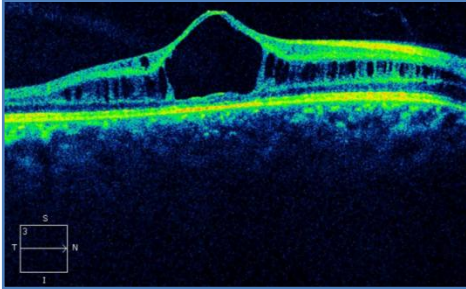


Fig. 5: sdoct hd 5line raster of right eye after treatment

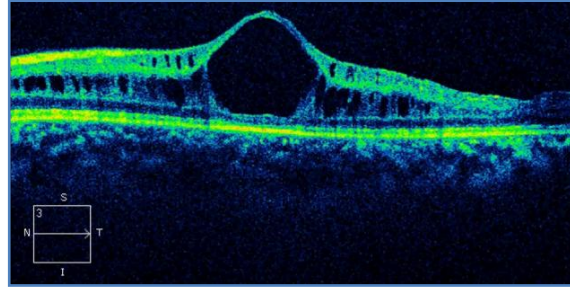


Fig. 6: sdoct hd 5line raster of left eye after treatment

AUTHORS:

1. Nagesha C.K.
2. Narendra P. Datti
3. Sugaranjini G.

PARTICULARS OF CONTRIBUTORS:

1. Assistant Professor, Department of Ophthalmology, Sri Devaraj Urs Academy of Higher Education and Research.
2. Professor & Head, Department of Ophthalmology, Sri Devaraj Urs Academy of Higher Education and Research.
3. Post Graduate Student, Department of Ophthalmology, Sri Devaraj Urs Academy of Higher Education and Research.

NAME ADDRESS EMAIL ID OF THE CORRESPONDING AUTHOR:

Dr. Nagesha C.K.,
Assistant Professor,
Department of Ophthalmology,
Sri Devaraj Urs Academy of Higher Education and
Research, Kolar.
E-mail: drnageshck_2006@yahoo.com

Date of Submission: 02/12/2013.

Date of Peer Review: 04/12/2013.

Date of Acceptance: 16/12/2013.

Date of Publishing: 17/01/2014.